

NO-NEEDLE JET ANESTHETIC TECHNIQUE FOR NO-SCALPEL VASECTOMY

RONALD S. WEISS* AND PHILIP S. LI

From the Department of Family Medicine, University of Ottawa (RSW), Ottawa, Ontario, Canada, and Center for Male Reproductive Medicine and Microsurgery, Cornell Institute for Reproductive Medicine, Department of Urology, Weill Cornell Medical Center of Cornell University, The New York Presbyterian University Hospital of Columbia and Cornell (PSL), New York, New York

ABSTRACT

Purpose: We describe a new, modified jet injection technique for local anesthesia for no-scalpel vasectomy without the use of a needle, which may minimize the fear of vasectomy in men due to the needle involved in local anesthesia.

Materials and Methods: A MadaJet Medical Injector (MADA Medical Products, Carlstadt, New Jersey) was used in this study to deliver a high pressure spray of 0.1 cc local anesthetic solution directly through the scrotal skin down onto the tissue around the vas. Two or 3 jet injections are delivered to each vas and a total of 4 to 6 suffice for the entire vasectomy.

Results: No-needle jet injection is remarkably effective for local anesthesia for no-scalpel vasectomy. The average volume of anesthetic solution per jet injection is 0.1 cc with 0.2 to 0.3 cc for each vas. Onset is almost immediate, within 10 to 20 seconds after injection. About 465 patients were anesthetized by the jet injection technique with great satisfaction. The average visual analog scale score for the pain of the jet injection itself was 1.71 of 10. The average visual analog scale score for the pain of subsequent vasectomy during the surgical procedure was 0.66 of 10 (median 0.2). No hematomas were noted. Patients experience the mild discomfort of a pinch, not unlike a rubber band, with the first injection.

Conclusions: No-needle anesthesia with jet injection is a new technique to deliver rapid onset of profound local anesthesia to the patient undergoing vasectomy. It is a simple and safe approach with high patient satisfaction, as reflected in low pain scores. The benefit of this technique without a needle is that it may decrease the fear of pain in men and enhance the popularity of vasectomy worldwide.

KEY WORDS: vasectomy; anesthesia; injections, jet; scrotum; needles

Vasectomy is a safe and effective method of permanent male contraception. In the United States it is used by almost 7% of all married couples and performed in approximately a half million men yearly, more than any other urological surgical procedure. Historically some men have shied away from vasectomy because they fear pain and the possible complications. However, in clinical practice one of the commonest voiced concerns is that of the needle for the injection of local anesthesia into and through the scrotal skin. Efforts to enhance the popularity of vasectomy have led groups in China to develop refined methods of no-scalpel vasectomy that minimize trauma, pain and complications.^{1–5} While the introduction of no-scalpel vasectomy has successfully allayed the fear of many men with regard to the scalpel, the success of Chinese groups in attaining these goals is evidenced by a complete reversal of the ratio of male-to-female sterilizations (now 3:1) in favor of vasectomy in the Sichuan province of China.⁶

The option of receiving local anesthesia without a needle is particularly welcome in many men, which may have some significant advantages for the popularity of vasectomy, especially in developing countries. Conventional vasal block needle anesthesia for no-scalpel vasectomy involves a 25 or 27 gauge 1½-inch needle, which is used to raise a wheal at the median raphe at the junction of the upper third and lower two-thirds of the scrotum. It is then advanced its full length toward the external inguinal ring on each side, where further

anesthetic solution is deposited (fig. 1, A).⁷ In 2001 Wilson initially described no-needle jet injection as an anesthetic technique using the MadaJet system for vasectomy.⁸ One of us (RSW) modified and refined the jet injection technique for vasectomy discussed in this report (fig. 1, B). The goal of this modified, no-needle jet anesthetic approach is to simplify the surgical technique and decrease the fear of vasectomy in men.

MATERIALS AND METHODS

General preparation. A warm room temperature (20C to 25C) is set up in advance to facilitate relaxation of the scrotal skin. The scrotal skin is shaved, preferably in advance, and the penis is retracted by a rubber band placed around the glans and secured with a clamp to the shirt of the patient.

Jet injector preparation. The MadaJet has been widely used in the fields of dermatology, cosmetic and plastic surgery, gynecology, dentistry and podiatry as well as for immunization (fig. 2, A).^{9–14} The injector is fully autoclavable for instrumental sterilization. A drop of lidocaine solution is placed over the seal on the injector head to promote a good seal with the filling chamber (fig. 2, B). The filling chamber is filled with approximately 4.5 cc anesthetic solution, that is 2% lidocaine without epinephrine (fig. 3, A). The jet injector assembly is then attached to the filling chamber (fig. 3, B). The main injector assembly is affixed and pumped back and forth, and fired several times to prime the mechanism and clear any potential debris or contaminants from the tip prior to the first use after filling (fig. 4, A). The spacer can be modified by carving out a 3 to 4 mm diameter notch to fit

Submitted for publication August 18, 2004.

* Correspondence: 29 Clemow Ave., Ottawa, Ontario, K1S 2B1 Canada (telephone: 613-235-3535; FAX: 613-237-8193; e-mail: rswiss@rogers.com).

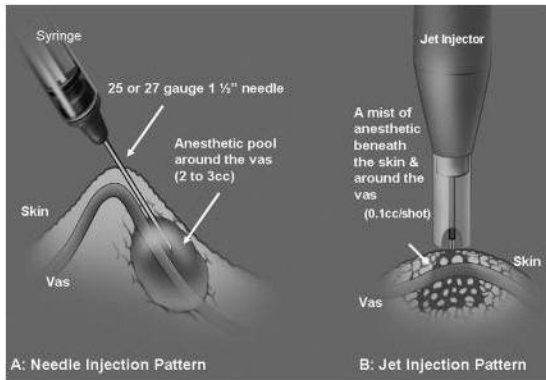


FIG. 1. Anesthetic dispersal patterns of jet vs needle injection. In needle injection pattern anesthesia is delivered by 25 or 27 gauge 1 1/2-inch needle along vas, creating anesthetic pool around vas to block vasal nerve (A). In jet injection pattern mist of lidocaine solution without epinephrine is delivered via high pressure injector through tiny head to beneath skin and throughout tissue around vas, resulting in more rapid absorption and less pain (B).

snugly over the vas while administering jet anesthesia (fig. 4, B and C)

Surgical preparation. With the surgeon standing on the right side of the patient the right vas deferens is fixed and separated from the spermatic cord vessels and manipulated to a superficial position under the scrotal skin. The vas is firmly trapped between the middle finger, index finger and thumb of the left hand (fig. 5, A). To ensure that the jet injector functions well the preloaded injector is fired once immediately before each use. After the scrotal skin is swabbed with alcohol the spacer covered tip of the injector is placed over the vas with gentle pressure just to the left lateral aspect of the median raphe at the junction of the upper third and lower two-thirds of the scrotum. Two or 3 injections are administered sequentially, proceeding from proximal to distal, 2 to 3 mm apart along the left lateral aspect of the median raphe. The left vas deferens is grasped in similar fashion with 2 or 3 sequential injections, proceeding from proximal to distal, at 2 to 3 mm apart along the right lateral aspect of the median raphe at the junction of the upper third and lower two-thirds of the scrotum, and adjacent to the previous 3 injections (fig. 5, B to D). Unlike a conventional vasal block with needle injection for no-scalpel vasectomy there is no skin wheal or local edema to cause a pinch following anesthetic administration. Moreover, jet injection has completely different dispersal patterns. It delivers a mist of lidocaine solution without epinephrine via a

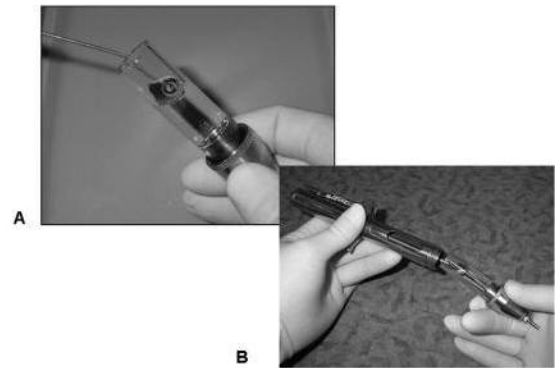


FIG. 3. About 4.5 to 5 ml lidocaine solution without epinephrine is loaded into fill chamber for injection (A). Main injector assembly is attached to filling chamber/headpiece (B).

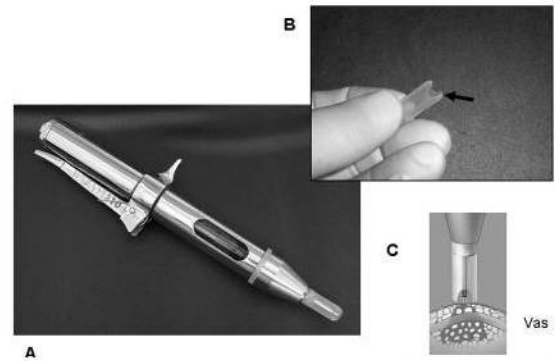


FIG. 4. Assembled injector is loaded with lidocaine solution (A) and special spacer (arrow) is placed on tip (B). Spacer can be modified by carving out 4 mm diameter notch to fit snugly over vas while administering anesthesia (C).

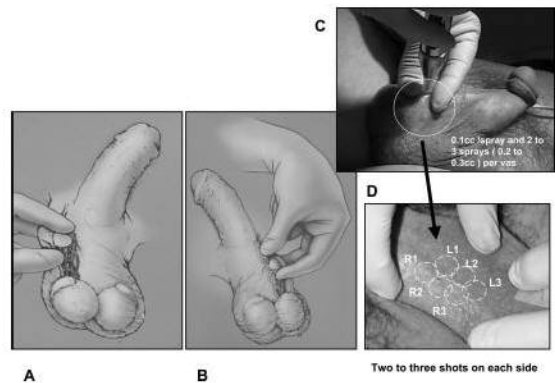


FIG. 5. Three finger technique is used to fix and isolate right (A) and left (B) sides of vas from spermatic cord. Injector is placed over vas and fired (C). Two or 3 injections are placed over each vas on right (R1, R2 and R3) and left (L1, L2 and L3) sides 4 mm apart and just lateral to median raphe at junction of upper third and lower two-thirds of scrotum (D).

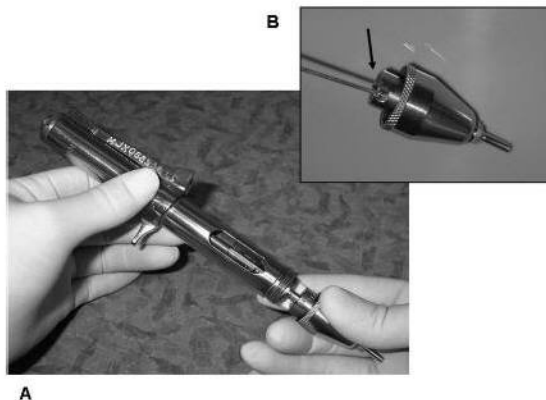


FIG. 2. Injector is primed by moving main assembly back and forth within headpiece several times prior to tightening (A). Few drops of lidocaine solution are placed on injector head to ensure good seal (B).

high pressure injector through a tiny opening on the head to beneath the skin. The anesthetic mist is rapidly absorbed throughout tissue around the vas with much less trauma (fig. 1). Therefore, jet injection is less painful than the needle. Finally, the injection sites are identified by a pinpoint area of blanching. The jet injector should be disinfected appropriately (eg with soaking in glutaraldehyde) prior to the next use.

Injections are placed such that the right vas is brought up and injected just under the left lateral aspect of the median raphe and the left vas is brought up and injected just under

the right lateral aspect of the median raphe. This achieves 2 results. 1) Surface anesthesia may be described as a series of intersecting circles at each injection point. The 4 to 6 intersecting circles provide sufficient surface anesthesia for performing the initial skin puncture and spreading in the no-scalpel vasectomy technique. 2) There will be sufficient anesthesia of the scrotal septum by this cross anesthesia, further decreasing the risk of intraoperative discomfort.

After the completion of jet injection and scrubbing with povidone-iodine solution the scrotal skin is washed with clear water based antiseptic solution prior to vasectomy. Patients were asked to complete a visual analog scale (VAS) questionnaire immediately following the completion of surgery. Information regarding preoperative anesthetic pain with no-needle injection and the subsequent pain of vasectomy on 2, 10 cm lines (0—no pain to 10—worst pain ever) were documented. A ruler was then used to measure the response in mm. When the response was between 2 values, the larger of the 2 values was recorded. The anesthetic and surgical records were kept in the physician's office.

RESULTS

In this study of 465 patients between March 2004 and June 2004 none required any additional anesthesia after the no-needle jet injection anesthetic technique. Three of the 465 cases were disqualified as a result of previous vasectomy with or without vasovasostomy. The average VAS pain score for jet injection itself was 1.71 of 10 (range 0 to 7.40, median 1.3). The average VAS pain score for vasectomy following jet injection was 0.66 of 10 (range 0 to 6.60, median 0.2). No hematomas were noted.

The average volume of anesthetic solution per injection was 0.1 cc. Therefore, the total volume used in an entire vasectomy procedure was about 0.6 cc, a fraction of that required using conventional needle delivery of up to 3 cc per vas and about 6 cc per vasectomy. The onset of anesthesia is almost immediate (average time between 10 and 20 seconds). The jet injection technique significantly decreased the volume of anesthetic solution. It cost approximately US\$0.07 dollar for the anesthesia. Therefore, it could lead to a significant cost savings in high volume vasectomy practices (see table). The cost of the MadaJet Medical Injector is US\$562, which must be factored into costs per injection (see table).

DISCUSSION

The major advantages of this jet injection technique are elimination of the needle for vasectomy and a decrease in the fear of vasectomy in men. No-needle jet injector anesthetic application is a safe, virtually painless and effective technique for vasectomy as well as for almost all primary care office small procedures. The anesthetic effect is almost immediate and it is more profound than that achieved by the needle. A small amount of anesthetic solution is forced through a tiny opening under high pressure, creating a fine mist stream that acts as a virtual needle, easily passing through the scrotal skin without requiring a needle. However, unlike a needle technique this fine stream spreads beneath the skin in a cone-shaped distribution, perfusing all tissue in its path (fig. 1). Normally the mist stream penetrates about 4 to 4.5 mm into tissue, which disperses to

approximately 5 to 6 mm in diameter. Injection leaves a pinpoint mark at the entry site that is easily recognizable in most men. This is less clear in nonwhite men and the surgeon may choose to mark the scrotum with a marking pen in these patients, so as not to lose the area of anesthetic application. It is not necessary to wait following injection and the surgeon may proceed immediately. However, one may choose to administer local anesthesia first and then prepare the sterile field. This has the advantage of affording the surgeon more time to set up prior to preparation of the sterile surgical field. In our experience there are rare cases in which jet injection anesthesia is less effective than the use of a needle. In particular, when the scrotal skin is thickened and ruddy, and when there has been previous scrotal surgery with adhesion, the surgeon would do better to perform a conventional vasal block by needle. Use of the jet injector also decreases the possibility of needle injury to the vas artery, which may lead to hematoma formation, one of the commonest post-vasectomy complications.¹⁴

Unlike conventional vasal block anesthesia as performed in no-scalpel vasectomy, which is administered after the sterile preparation, jet injectors may be used in many patients sequentially as long as the devices are partially immersed in an appropriate disinfectant. Previous experience with jet injectors for mass immunization programs led to contamination with blood-borne contaminants. Earlier designs of these injectors and insufficient attention to disinfection regimens between applications may have made it more likely for such contamination to occur. However, to our knowledge there have been no reports of the transmission of blood-borne contaminants among patients when this new type of injector is used in this manner.

The jet injectors require regular maintenance and inspection. The MadaJet System should be disinfected between patients in a glutaraldehyde solution or another appropriate disinfectant solution (cold sterilization times vary by solution). In addition, the spacer tips can be changed between uses and the units may be autoclaved in their entirety on a regular basis. Finally, firing the injectors before and after use helps clear any possible debris, further decreasing the risk of transmission of blood-borne contaminants. With continued use wear and tear causes deterioration of the numerous rubber O rings that maintain seals within the unit. As a result, the unit will not function properly and the anesthetic effect may be compromised. With some guidance provided by the manufacturer the operator may replace these O rings and other seals or simply let the manufacturer do it.

While the jet injector eliminates needle stick injury and syringe waste management, it introduces the possibility of self-injection of the operator's third digit through an exit wound when using the 3 finger no-scalpel vasectomy technique. We have experienced this on a few occasions only when the injector was empty of anesthetic solution. However, the theoretical possibility of an exit wound exists and the surgeon is advised to use protection. A protective finger thimble may provide some protection. Custom molded thimbles are available for this purpose. Unfortunately the use of a thimble creates an insensate barrier to the third digit when palpating the vas deferens. The surgeon may find that it takes some accommodation to maintain the 3 finger technique when only the thumb and index fingers maintain sensation. It is essential to use this technique in our view to ensure that the jet injection stream passes through the vas and not other scrotal vessels with the attendant risk of hematoma. It is not unusual with a practiced technique to witness subfascial congestion due to the disruption of smaller vessels by the jet stream.

When perfected, this anesthetic technique allows virtually pain-free vasectomy to be performed with a minimal risk of hematoma. Jet injection eliminates local edema and the onset of anesthesia is more rapid than with the needle technique. The

Jet injection for local anesthesia in no-scalpel vasectomy

| Per Vasectomy | Conventional Needle Anesthesia | No-Needle Jet Injection |
|-----------------------------|--------------------------------|-------------------------|
| Av lidocaine vol (cc) | 6 | 0.6 |
| Av time to anesthesia onset | 2–3 Mins | 10–20 Secs |
| Injection cost (US\$) | 0.79 | 0.07* |

* Not including capital outlay for injector.

avoidance of multiple punctures and excess needle injection may also minimize the risk of hematoma. More importantly, it also decreases the cost of medical waste. Little research currently exists comparing conventional local anesthesia by needle delivery vs by the jet injection technique. A study that compared the subcutaneous administration of midazolam demonstrated less discomfort with jet injection.¹⁰ While these results were not statistically significant, reports of persistent discomfort at the injection site were greater in the needle group. A number of studies have shown the superiority of jet injection for the delivery of anesthesia prior to dental surgery and for intravenous catheterization.¹¹⁻¹³ A multicenter study comparing jet injection anesthesia with needle delivery for no-scalpel vasectomy has been proposed. Like any new surgical technique, it requires a short learning curve to master at the beginning and 5 to 10 cases to achieve proficiency. It requires the performance of a series of precise maneuvers executed in a specific order with accuracy.

CONCLUSIONS

Our patients respond overwhelmingly favorably to the no-needle jet anesthetic method for vasectomy. Men have feared vasectomy for various reasons, among them needle phobia. It decreases the risk of needle stick injury and limits syringe waste management. It is a safe, economical and virtually painless anesthetic application. Since eliminating the scalpel for vasectomy has enhanced the acceptance of vasectomy in many countries, the no-needle jet injection technique may decrease the fear of this procedure in patients and encourage more men to undergo surgical sterilization. No hematomas were noted in this study group.

Dr. Marc Goldstein and Dr. Barry Rich provided assistance and advice. Custom molded thimbles are available from David Batten, Ottawa, Ontario, Canada.

REFERENCES

1. Li, S., Goldstein, M., Zhu, J. and Huber, D.: The no-scalpel vasectomy. *J Urol*, **145**: 341, 1991

2. Huber, D.: No-scalpel vasectomy: the transfer of a refined surgical technique from China to other countries. *Adv Contracept*, **5**: 217, 1989
3. Nirapathpongporn, A., Huber, D. H. and Krieger, J. N.: No-scalpel vasectomy at the King's birthday vasectomy festival. *Lancet*, **335**: 894, 1990
4. Viladoms, J. M. and Li, P. S.: Vasectomía sin Bisturí. *Arch Esp Urol*, **47**: 695, 1994
5. Kumar, V., Kaza, R. M., Singh, I., Singhal, S. and Kumaran, V.: An evaluation of the no-scalpel vasectomy technique. *BJU Int*, **83**: 283, 1999
6. Liu, X. and Li, S.: Vasal sterilization in China. *Contraception*, **48**: 255, 1993
7. Li, P. S., Li, S. Q., Schlegel, P. N. and Goldstein, M.: External spermatic sheath injection for vasal nerve block. *Urology*, **39**: 173, 1992
8. Wilson, C. L.: No-needle anesthetic for no-scalpel vasectomy. *Am Fam Physician*, **63**: 1295, 2001
9. Ellis, G. L. and Owens, A.: The efficacy and acceptability of using a jet injector in performing digital blocks. *Am J Emerg Med*, **11**: 648, 1993
10. Bennett, J., Nichols, F., Rosenblum, M. and Condry, J.: Subcutaneous administration of midazolam: a comparison of the Bioject jet injector with the conventional syringe and needle. *J Oral Maxillofac Surg*, **56**: 1249, 1998
11. Munshi, A. K., Hegde, A. and Bashir, N.: Clinical evaluation of the efficacy of anesthesia and patient preference using the needle-less jet syringe in pediatric dental practice. *J Clin Pediatr Dent*, **25**: 131, 2001
12. Zsigmond, E. K., Darby, P., Koenig, H. M. and Goll, E. F.: Painless intravenous catheterization by intradermal jet injection of lidocaine: a randomized trial. *J Clin Anesth*, **11**: 87, 1999
13. Cooper, J. A., Bromley, L. M., Baranowski, A. P. and Barker, S. G.: Evaluation of a needle-free injection system for local anaesthesia prior to venous cannulation. *Anesthesia*, **55**: 247, 2000
14. Goldstein, M., Young, G. P. H. and Einer-Jensen, N.: Testicular artery damage due to infiltration with a fine gauge needle: experimental evidence suggesting that blind cord block should be abandoned. *Surg Forum*, **24**: 653, 1983